

Current Options in Clipping Versus Coiling of Intracranial Aneurysms: to Clip, to Coil, to Wait and Watch

Thomas C. O'rigitano, MD, PhD, FACS

KEYWORDS

- Cerebral aneurysm • Subarachnoid hemorrhage
- Endovascular treatment

INTERNATIONAL SUBARACHNOID ANEURYSM TRIAL

Interpretation: in patients with ruptured intracranial aneurysms for which endovascular coiling and neurosurgical clipping are therapeutic options, the outcome in terms of survival free of disability at 1 year is significantly better with endovascular coiling. The data suggest that long-term risks of further bleeding from a treated aneurysm are low with either treatment, although somewhat more frequent with endovascular coiling.¹

INTERNATIONAL SUBARACHNOID ANEURYSM TRIAL FOLLOW-UP STUDY

Interpretation: in patients with intracranial aneurysms suitable for both treatments, endovascular coiling is more likely to result in independent survival at 1 year than neurosurgical clipping; the survival benefit continues for at least 7 years. The risk of rebleeding is low but more common after endovascular coiling than after neurosurgical clipping.²

INTERNATIONAL STUDY OF UNRUPTURED INTRACRANIAL ANEURYSMS

Interpretation: many factors are involved in the management of patients with unruptured intracranial aneurysms. Site, size, and group-specific risks of the

natural history should be compared with site, size, and age-specific risks of repair for each patient.³

Introduction

The treatment of intracranial aneurysms presents patients and practitioners with a challenging clinical paradigm encompassing the potential for catastrophe, cure, or chronic follow-up. Successful management entails a combination of thoughtful surgical and/or medical intervention and management.^{4–9} Optimizing outcome requires an integration of technical skills (surgical and interventional), facilities, experience, and technology. Since 1981 several important studies have added significant but controversial data to the intellectual resources used in the decision paradigm for the management of intracranial aneurysms.^{1,3,10,11} Practitioners today are faced with a complex decision tree of whether or not to clip, coil, or wait and watch. This article focuses on presenting a pragmatic equipoise for managing patients who have intracranial aneurysms.

EPIDEMIOLOGY: FEW ANEURYSMS RUPTURE, BUT WHEN THEY DO, OUTCOMES ARE HARSH

The incidence of aneurysmal rupture is between 6 and 12 per 100,000, yielding 15,000 to 30,000 new aneurysmal subarachnoid hemorrhages (SAHs) annually.^{12–18} Overall mortality at 6 months is

This article originally appeared in the November 2006 issue of Neurologic Clinics.

Department of Neurological Surgery, Stritch School of Medicine, Loyola University Medical Center, 2160 South First Avenue, Maywood, IL 60153, USA

E-mail address: torigit@lumc.edu

Neurosurg Clin N Am 19 (2008) 469–476

doi:10.1016/j.neu.2008.07.015

1042-3680/08/\$ – see front matter © 2008 Elsevier Inc. All rights reserved.

estimated to be between 40% and 50%, with 15% of patients expiring before reaching the hospital and an additional 25% within 24 hours.^{19,20} Only one third of those who survive have functional independent lives.^{19,21–24} Treatment of a ruptured aneurysm is imperative. Rebleeding has a catastrophic morbidity of 48% to 78%.^{25–27}

TO WAIT AND WATCH

Treatment of unruptured aneurysms is exceptionally more controversial with recent data from the International Study of Unruptured Intracranial Aneurysms (ISUIA)³ adding important natural history data. This landmark study reveals that 5-year cumulative rupture rates for patients who (1) did not have a history of SAH and (2) had aneurysms located on the internal carotid artery, anterior cerebral artery, or middle cerebral artery were 0%, 2.6%, 14.5%, and 40% for aneurysms that were less than 7 mm, 7 to 12 mm, 13 to 24 mm, and 25 mm or greater, respectively. These rates are compared with rates of 2.5%, 14.5%, 18.4%, and 50%, respectively, for the same size categories involving posterior circulation and posterior communicating artery aneurysms (**Fig. 1**).³ Cavernous aneurysms less than 13 mm seemed totally benign. Unruptured aneurysms associated with previous SAH from another aneurysm had statistically higher rupture rates (**Table 1** and see **Fig. 1**). These results are regarded as controversial by the neurosurgical community in light of previously published data^{11,27–29} in which the most common aneurysms to rupture were 7 mm with an incidence of 1% to 2% per year. Further exacerbating the controversy are findings that demonstrate that for aneurysms less than 7 mm in diameter in patients who have not had a previous SAH, the rupture rate is low (0.1%/year) and, accordingly, it would be difficult for any treatment to improve on the natural history of these lesions.³ This study and its wide distribution to the lay press has led to a profound change in the counsel that the neuroscience community gives to patients found to harbor small unruptured aneurysms. It should be remembered that this data-based conservation must be interpreted in regard to the realities of individual patient experiences. Low rupture rates do not mean no rupture. Aneurysms less than 7 mm can and will rupture, and patients bear the morbidity and mortality of aneurysmal SAH. Furthermore, preliminary neuropsychologic studies demonstrate that patients who harbor and know they have untreated intracranial aneurysms have a reduced quality of life.³⁰ Managing anxiety in this patient population can be challenging when the following questions remain

unclear: (1) How often should patients be re-studied? (2) Which modality is best for follow-up (angiography, magnetic resonance angiography, or CT angiography)? (3) How much change in an aneurysm should prompt intervention? (4) How should patients modify their lifestyle to accommodate an aneurysm? and (5) What are the medical-legal implications of observation?

TO CLIP OR TO COIL

Once it is determined that an aneurysm should be or will be treated, two options prevail: endovascular embolization and open surgical clipping. The goal of either treatment should be complete and lasting exclusion of an aneurysm from cerebral circulation with preservation of parent, branching, and perforating arteries.

The gold standard for aneurysm obliteration is open surgery. The International Subarachnoid Aneurysm Trial (ISAT) and the International Study of Unruptured Intracranial Aneurysms (ISUIA)^{1–3} compared interventional endovascular treatment to open surgical clipping. Both landmark studies challenge conventional wisdom and patient management. It is imperative when interpreting these studies to be able to place in equipoise the patient population studied, the clinical talent on hand, and the outcomes assessed with individual patients. It is the generalization of the results to each and every patient wherein lies the rub. Entry criteria to ISAT required subjective agreement that an aneurysm could be treated by either endovascular or open surgery. Many aneurysms failed to meet that criteria: (1) patients who had life-threatening intracerebral or subdural hematomas; (2) incompatible neck-to-dome ratios; (3) parent artery or branch artery incorporation into the dome; (4) fusiform aneurysms; (5) thrombotic aneurysms; (6) giants; (7) blisters; (8) pseudo/traumatic aneurysms; (9) those with mass effect; and (10) those that had failed repeated endovascular treatment. In the ISAT study, 9559 patients who had SAH were assessed; 7416 were excluded (671 refused and 6,745 for “other reasons”); and 2143 were randomized. Outcomes at 1 year are summarized in **Table 2** and demonstrate that in this patient population with ruptured intracranial aneurysms for which endovascular coiling and neurosurgical clipping are therapeutic options, the outcomes in terms of survival free of disability at 1 year is significantly better with endovascular coiling. The follow-up ISAT article validates these findings.² Patients in both ISAT studies (1) were 88% grade I–II; (2) had 93% small aneurysms less than 10 mm; (3) had 97% anterior circulation; and (4) were 99% European. Mortality was not significantly different. Rebleed rate was

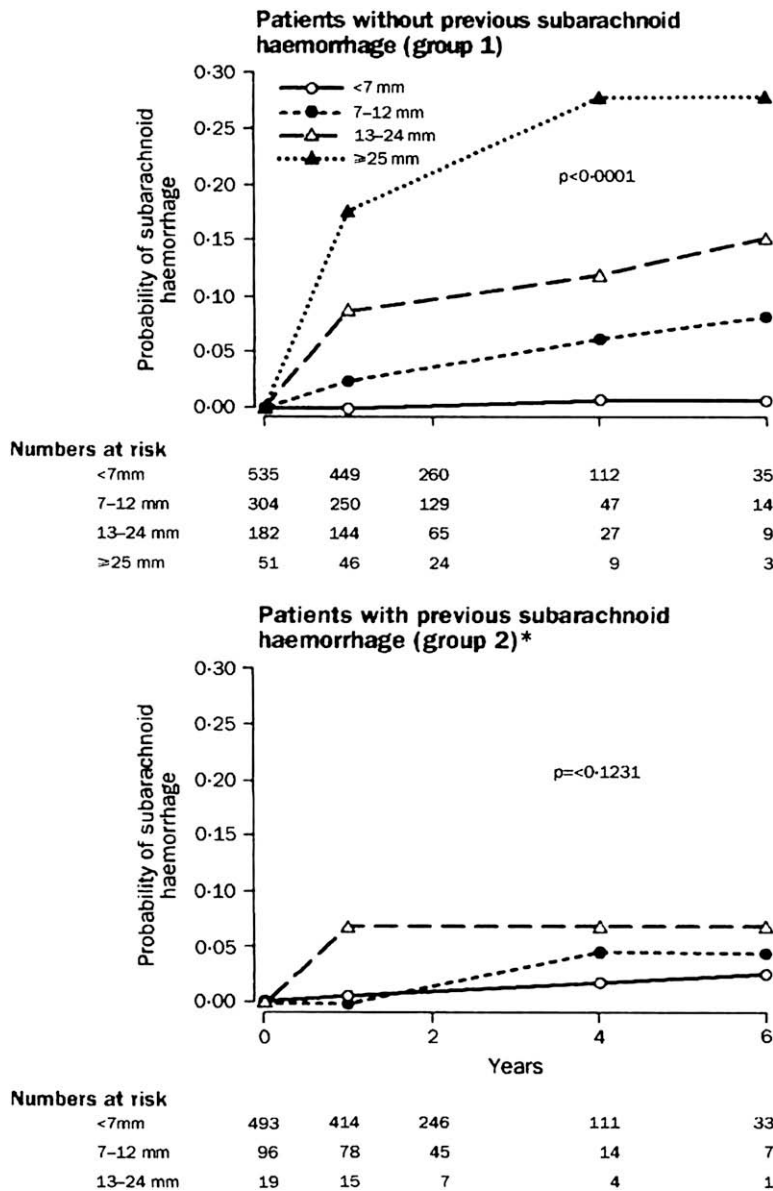


Fig. 1. Probability of subarachnoid hemorrhage over time for patients who did not have surgery. Data not shown for the ≥ 25 -mm group because of small sample size. (From Wiebers DO, Whisnant JP, Huston J 3rd, et al. Unruptured intracranial aneurysms: natural history, clinical outcome, and risks of surgical and endovascular treatment. *Lancet* 2003;362:103-10; with permission.)

approximately 3 times higher in the endovascular group than the surgical group (2.6% versus 0.9%). Retreatment was 4 times as prevalent in the endovascular group than with open surgery (136 versus 34) (Table 3).

The completeness and durability of endovascular treatment should be considered in light of actual data in the surgical literature on partially treated aneurysms where symptomatic rehemorrhage is a late phenomenon reported to occur between 4 and 20 years, with a mean of approximately 10 years and rebleed rates of 71% to 79%.³¹⁻³⁴ These results suggest that a partially treated aneurysm is not a benign pathology and 1-year follow-ups may not define the natural

history of the disease. Reinforcing the issue of chronicity of the pathology, the Dutch aneurysm screening after surgical treatment for ruptured aneurysms (ASTRA) Study Group demonstrates a 16% incidence of new aneurysm formation over a 15-year period in 610 patients who underwent surgical clipping of a ruptured aneurysm.³⁵ Patients who have intracerebral aneurysms may represent a unique form of vasculopathies requiring long-term surveillance.

The fastest growing population of patients who have aneurysms is those who have partially obliterated coiled aneurysms. In a review of 48 studies comprising 1383 patients treated with coil embolization, a permanent complication was observed in

Table 1 Five-year cumulative rupture rates according to size and location of unruptured aneurysm					
	< 7 mm		7–12 mm	12–24 mm	> 25 mm
	Group 1	Group 2			
Cavernous carotid artery (n = 210)	0	0	0	3%	6.4%
AC/MC (n = 1037)	0	1.5%	2.6%	14.5	40%
Post P comm (n = 445)	2.5%	3.4%	14.5%	18.4%	50%

Abbreviations: AC, anterior communicating or anterior cerebral artery; IC, internal carotid artery (not cavernous carotid artery); MC, middle cerebral artery; Post P comm, vertebrobasilar posterior cerebral arterial system or the posterior communicating artery.
From Wiebers DO, Whisnant JP, Huston J 3rd, et al. Unruptured intracranial aneurysms: natural history, clinical outcome, and risks of surgical and endovascular treatment. Lancet 2003;362:103–10; with permission.

3.7%. Occlusions of greater than 90% were achieved in 90%.³⁶ Therefore, approximately 10% had significant residual. Outcomes such as these have led to several patient management nuances, which data have yet to address. A new vernacular has evolved. Terms, such as (1) greater than 95% occlusion, (2) stable residual neck at 2 years, (3) protected dome, and (4) near complete occlusion, now are part of the medical record. These terms and the anxiety they generate in patients who must bear them are difficult to manage until long-term studies are completed. Surgical management of recurrent partially coiled aneurysms seems technically more difficult and significantly underdeveloped.^{37–41}

During the past decade, open surgical management has evolved as a consequence of subspecialization, technical innovation, and influence of endovascular therapy. The choice of open surgical intervention is influenced by several factors: complexity of the aneurysm, size (too small or too large), geometry, unfavorable dome-to-neck ratio, access (inability to navigate delivery system to aneurysm site), and anatomy (parent artery, branch artery, or perforator incorporation into neck). The cornerstone of open surgical management is microsurgical dissection of the subarachnoid planes, proximal and distal vascular control, direct visualization of clip application, and puncture verification of total aneurysm obliteration.^{42,43} Surgical innovations, such as

Table 2 Outcome at 1 year in 1595 patients (primary outcome)			
		Endovascular Treatment (n = 801)	Neurosurgery (n = 793)
Modified rankin scale			
0	No symptoms	207 (25.8%)	152 (19.2%)
1	Minor symptoms	217 (27.7%)	220 (27.7%)
2	Some restriction in lifestyle (0–2 inclusive)	187 (23.4%) 611 (76.3%)	178 (22.4%) 550 (69.4%)
3	Significant restriction in lifestyle	80 (10%)	106 (13.4%)
4	Partly dependent	24 (3%)	32 (4%)
5	Fully dependent	21 (2.6%)	25 (3.2%)
6	Dead (3–6 inclusive)	65 (8.1%) 190 (23.7%)	80 (10.1%) 243 (30.6%)

Data in italics are primary outcome.
From Molyneux A, Kerr R, Stratton I, et al. International Subarachnoid Aneurysm Trial (ISAT) of neurosurgical clipping versus endovascular coiling in 2143 patients with ruptured intracranial aneurysms: a randomised trial. Lancet 2002;360:1267–74; with permission.

Table 3
Time to second procedure on same aneurysm

	< 30 Days	30 Days–1 Year	> 1 Year	Total
Allocated endovascular				
Second procedure endovascular	14	30	9	52
Second procedure neurosurgery	67	10	6	83
Allocated neurosurgery				
Second procedure endovascular	23	5	1	30
Second procedure neurosurgery	4	0	0	4

From Molyneux A, Kerr R, Stratton I, et al. International Subarachnoid Aneurysm Trial (ISAT) of neurosurgical clipping versus endovascular coiling in 2143 patients with ruptured intracranial aneurysms: a randomised trial. *Lancet* 2002;360:1267–74; with permission.

cranial base approaches, have advantaged these goals.^{44–48} Intraoperative angiography is a powerful interdiction confirming parent or branch artery patency and aneurysm obliteration.^{49–55} Open surgical procedures, although advantaging a more durable and complete obliteration, do so at a higher risk related to neurobehavioral outcomes compared with their endovascularly treated counterparts.^{2,3,56–58}

Either clipped or coiled, management of intracranial aneurysms is advantaged in centers where both modalities are available and a volume of SAHs are treated routinely.^{4–9} Volume drives expertise, technology, facilities, and ancillaries necessary for the complexities associated with the diagnosis, intervention, and medical management of patients who have SAH. Mortality rates in hospital centers managing fewer than 10 SAH per year were 40% higher than those in high volume centers managing more than 35 SAH per year.⁴ The ability to perform intracranial angioplasty had a 16% risk reduction for death.⁵ The California SAH study of 21,540 patients who had SAH and were admitted revealed 40% lower odds of mortality when 21 or more cases per year were managed.⁶ These results were similar to a New York study, where a 43% reduction in mortality was seen for craniotomies for aneurysm in centers that performed 30 or more cases per year.⁷ Size (of case load) does matter.

TREATMENT CONSIDERATIONS

Considering the previous information, what should be recommended for patients who have an intracranial aneurysm? What is known for sure?

- Patients who have intracranial aneurysms should be referred to centers that have interventional and surgical capacities. These centers should contain dedicated ICUs and technologies, such as intraoperative

angiography, biplane angiography with 3-D capabilities, and transcranial Doppler, and capabilities to do cerebral blood flow studies. Having this, the full capacity to manage the interventional and medical aspects of SAH is advantaged.

- Interventionalists and open surgeons should act as partners, not competitors. All patients should be assessed clinically and radiologically by both practitioners before a decision for treatment is decided.
- The goal of aneurysm management is complete, durable obliteration without neurologic consequence. Experienced teams understand their own capacities, limitations, and patient ability to tolerate each intervention. Surgical clipping surely is a more invasive procedure but also more durable.
- Initial evaluation by both practitioners advantages consideration for placement of an external ventricular drain in poor grade patients or in patients whose ventricles are increasing in size before systemic heparinization associated with endovascular intervention.
- The initial angiography is done best by interventionalists with an open surgeon present. This allows for real-time decision making. Angiographic runs, which demonstrate collateral circulation, are obtained to facilitate surgical intervention should temporary occlusion be necessary. The 3-D reconstruction is invaluable to assess more accurately dome-to-neck ratio and parent artery or branch orientation to neck and enhances surgical view for clip placement and vessel reconstruction. After review, an experienced team knows what their personal experience is for each aneurysm location relative to success. Literature values are other teams' results.

- At the author's institution, the right of first attempt goes to an interventionalist unless aneurysms are clearly noncoilable, including those with a wide neck, blebs, those that are geometrically complex with incorporation of branch artery, those with inability to navigate delivery system, those that are partially thrombosed fusiform, giants, and those in patients who prefer open surgery.
- Much can be learned by a surgeon observing microcatheter analysis and initial placement of the framing coil. Remember, the goal is complete angiographic obliteration. If the framing coil does not seat or does so with significant asymmetry, leaving a portion of the neck uncovered, the likelihood of complete obliteration declines. Certainly balloon- or stent-assisted coiling is an option. Each adds risk. Stent-assisted coiling requires use of antiplatelet agents, a risk consideration at least in patients who have ruptured aneurysm. Stent-assisted and balloon-assisted interventions are not part of the ISAT or ISUIA data. A classical aneurysm for residual neck after coiling is the "simple" posterior communicating artery aneurysm. It often has an oblong neck, lending itself to residual dog ear and potential for regrowth. Alternatively, a successful strategy can be to treat, recognizing the small residual, getting patients through the acute phase of their SAH, and returning electively with stent placement when patients can tolerate the antiplatelet agents.
- The ISAT and ISUIA studies are statistically significant contributors to the literature on the treatment of cerebral aneurysms. They are not without limitations.^{59,60} (Readers are encouraged to review these references.)
- Treatment of intracranial aneurysms involves many factors: patient preference and demographics; aneurysm size, site, geometry, access, and intrinsic; practitioner experience and availability; facility; technology; and ancillaries. Volume counts. Teamwork enhances. Management should be individualized.

REFERENCES

1. Molyneux A, Kerr R, Stratton I, et al. International Subarachnoid Aneurysm Trial (ISAT) of neurosurgical clipping versus endovascular coiling in 2143 patients with ruptured intracranial aneurysms: a randomised trial. *Lancet* 2002;360:1267–74.
2. Molyneux AJ, Kerr RS, Yu LM, et al. International Subarachnoid Aneurysm Trial (ISAT) of neurosurgical clipping versus endovascular coiling in 2143 patients with ruptured intracranial aneurysms: a randomised comparison of effects on survival, dependency, seizures, rebleeding, subgroups, and aneurysm occlusion. *Lancet* 2005;366:809–17.
3. Wiebers DO, Whisnant JP, Huston J 3rd, et al. Unruptured intracranial aneurysms: natural history, clinical outcome, and risks of surgical and endovascular treatment. *Lancet* 2003;362:103–10.
4. Cross DT 3rd, Tirschwell DL, Clark MA, et al. Mortality rates after subarachnoid hemorrhage: variations according to hospital case volume in 18 states. *J Neurosurg* 2003;99:810–7.
5. Johnston SC. Effect of endovascular services and hospital volume on cerebral aneurysm treatment outcomes. *Stroke* 2000;31:111–7.
6. Bardach NS, Zhao S, Gress DR, et al. Association between subarachnoid hemorrhage outcomes and number of cases treated at California hospitals. *Stroke* 2002;33(7):1851–6.
7. Solomon RA, Mayer SA, Tarmey JJ. Relationship between the volume of craniotomies for cerebral aneurysm performed at New York state hospitals and in-hospital mortality. *Stroke* 1996;27:13–7.
8. Cowan JA Jr, Dimick JB, Wainess RM, et al. Outcomes after cerebral aneurysm clip occlusion in the United States: the need for evidence-based hospital referral. *J Neurosurg* 2003;99:947–52.
9. Heros RC. Case volume and outcome. *J Neurosurg* 2003;99:945–6 [discussion: 946].
10. International Study of Unruptured Intracranial Aneurysms Investigators. Unruptured intracranial aneurysms—risk of rupture and risks of surgical intervention. *N Engl J Med* 1998;339:1725–33.
11. Sahs AL. Aneurysmal subarachnoid hemorrhage: report of the cooperative study. Baltimore: Urban & Schwarzenberg; 1981.
12. Bederson JB, Awad IA, Wiebers DO, et al. Recommendations for the management of patients with unruptured intracranial aneurysms: a statement for healthcare professionals from the Stroke Council of the American Heart Association. *Stroke* 2000;31:2742–50.
13. van Gijn J, Rinkel GJ. Subarachnoid haemorrhage: diagnosis, causes and management. *Brain* 2001; 124(Pt 2):249–78.
14. Inagawa T, Hirano A. Autopsy study of unruptured incidental intracranial aneurysms. *Surg Neurol* 1990;34:361–5.
15. Mayberg MR, Batjer HH, Dacey R, et al. Guidelines for the management of aneurysmal subarachnoid hemorrhage. A statement for healthcare professionals from a special writing group of the Stroke Council, American Heart Association. *Circulation* 1994;90:2592–605.

16. Phillips LH 2nd, Whisnant JP, et al. The unchanging pattern of subarachnoid hemorrhage in a community. *Neurology* 1980;30:1034–40.
17. Ingall TJ, Whisnant JP, Wiebers DO, et al. Has there been a decline in subarachnoid hemorrhage mortality? *Stroke* 1989;20:718–24.
18. Kassell NF, Drake CG. Timing of aneurysm surgery. *Neurosurgery* 1982;10:514–9.
19. Hop JW, Rinkel GJ, Algra A, et al. Case-fatality rates and functional outcome after subarachnoid hemorrhage: a systematic review. *Stroke* 1997;28:660–4.
20. Mayberg MR. A clinical update on the diagnosis and treatment of subarachnoid hemorrhage: focus on medical management. *A CME Clinical Reference Compendium* 2004;January. p. 5–11.
21. Kassell NF, Torner JC. The International Cooperative Study on Timing of Aneurysm Surgery—an update. *Stroke* 1984;15:566–70.
22. Locksley HB. Natural history of subarachnoid hemorrhage, intracranial aneurysms and arteriovenous malformations. Based on 6368 cases in the cooperative study. *J Neurosurg* 1966;25:219–39.
23. Locksley HB. Natural history of subarachnoid hemorrhage, intracranial aneurysms and arteriovenous malformations. *J Neurosurg* 1966;25:321–68.
24. Suzuki J, Hori S, Sakurai Y. Intracranial aneurysms in the neurosurgical clinics in Japan. *J Neurosurg* 1971;35:34–9.
25. Nishioka H, Torner JC, Graf CJ, et al. Cooperative study of intracranial aneurysms and subarachnoid hemorrhage: a long-term prognostic study. II. Ruptured intracranial aneurysms managed conservatively. *Arch Neurol* 1984;41:1142–6.
26. Kassell NF, Torner JC. Aneurysmal rebleeding: a preliminary report from the Cooperative Aneurysm Study. *Neurosurgery* 1983;13:479–81.
27. Jane JA, Winn HR, Richardson AE. The natural history of intracranial aneurysms: rebleeding rates during the acute and long term period and implication for surgical management. *Clin Neurosurg* 1977;24:176–84.
28. Kassell NF, Torner JC. Size of intracranial aneurysms. *Neurosurgery* 1983;12:291–7.
29. Winn HR, Richardson AE, Jane JA. The long-term prognosis in untreated cerebral aneurysms: I. The incidence of late hemorrhage in cerebral aneurysm: a 10-year evaluation of 364 patients. *Ann Neurol* 1977;1:358–70.
30. van der Schaaf IC, Brilstra EH, Rinkel GJ, et al. Quality of life, anxiety, and depression in patients with an untreated intracranial aneurysm or arteriovenous malformation. *Stroke* 2002;33:440–3.
31. Drake CG, Vanderlinden RG. The late consequences of incomplete surgical treatment of cerebral aneurysms. *J Neurosurg* 1967;27:226–38.
32. Sato S, Suzuki J. Prognosis in cases of intracranial aneurysm after incomplete direct operations. *Acta Neurochir (Wien)* 1971;24:245–52.
33. Lin T, Fox AJ, Drake CG. Regrowth of aneurysm sacs from residual neck following aneurysm clipping. *J Neurosurg* 1989;70:556–60.
34. Giannotta SL, Litofsky NS. Reoperative management of intracranial aneurysms. *J Neurosurg* 1995;83:387–93.
35. Werner MJH, van der Schaaf IC, Velthuis BK, et al. Follow-up screening after subarachnoid haemorrhage: frequency and determinants of new aneurysms and enlargements of existing aneurysms. *Brain* 2005;128(Pt10):2421–9 Epub 2005 Jul 6.
36. Brilstra EH, Rinkel GJ, van der Graaf Y, et al. Treatment of intracranial aneurysms by embolization with coils: a systematic review. *Stroke* 1999;30:470–6.
37. Deinsberger W, Mewes H, Traupe H, et al. Surgical management of previously coiled intracranial aneurysms. *Br J Neurosurg* 2003;17:149–54.
38. Thornton J, Dovey Z, Alazzaz A, et al. Surgery following endovascular coiling of intracranial aneurysms. *Surg Neurol* 2000;54:352–60.
39. Civit T, Auque J, Marchal JC, et al. Aneurysm clipping after endovascular treatment with coils: a report of eight patients. *Neurosurgery* 1996;38:955–60 [discussion: 960–1].
40. Veznedaroglu E, Benitez RP, Rosenwasser RH. Surgically treated aneurysms previously coiled: lessons learned. *Neurosurgery* 2004;54:300–3 [discussion: 303–5].
41. Zhang YJ, Barrow DL, Cawley CM, et al. Neurosurgical management of intracranial aneurysms previously treated with endovascular therapy. *Neurosurgery* 2003;52:283–93 [discussion: 293–5].
42. Yasargil MG, Kasdaglis K, Jain KK, et al. Anatomical observations of the subarachnoid cisterns of the brain during surgery. *J Neurosurg* 1976;44:298–302.
43. Yasargil MG, Fox JL. The microsurgical approach to intracranial aneurysms. *Surg Neurol* 1975;3:7–14.
44. Origiano TC, Anderson DE, Tarassoli Y, et al. Skull base approaches to complex cerebral aneurysms. *Surg Neurol* 1993;40:339–46.
45. Sekhar LN, De Oliveira E. *Cranial microsurgery: approaches and techniques*. New York: Thieme Medical Publishers; 1999.
46. Dolenc VV. A combined epi- and subdural direct approach to carotid-ophthalmic artery aneurysms. *J Neurosurg* 1985;62:667–72.
47. Heros RC, Lee SH. The combined pterional/anterior temporal approach for aneurysms of the upper basilar complex: technical report. *Neurosurgery* 1993;33:244–50 [discussion: 250–1].
48. Sekhar LN, Kalia KK, Yonas H, et al. Cranial base approaches to intracranial aneurysms in the

- subarachnoid space. *Neurosurgery* 1994;35:472–81 [discussion: 481–3].
49. Martin NA, Bentson J, Vinuela F, et al. Intraoperative digital subtraction angiography and the surgical treatment of intracranial aneurysms and vascular malformations. *J Neurosurg* 1990;73:526–33.
 50. Barrow DL, Boyer KL, Joseph GJ. Intraoperative angiography in the management of neurovascular disorders. *Neurosurgery* 1992;30:153–9.
 51. Alexander TD, Macdonald RL, Weir B, et al. Intraoperative angiography in cerebral aneurysm surgery: a prospective study of 100 craniotomies. *Neurosurgery* 1996;39:10–7 [discussion: 17–8].
 52. Origitano TC, Schwartz K, Anderson D, et al. Optimal clip application and intraoperative angiography for intracranial aneurysms. *Surg Neurol* 1999;51: 117–24 [discussion: 124–8].
 53. Tang G, Cawley CM, Dion JE, et al. Intraoperative angiography during aneurysm surgery: a prospective evaluation of efficacy. *J Neurosurg* 2002;96:993–9.
 54. Chiang VL, Gailloud P, Murphy KJ, et al. Routine intraoperative angiography during aneurysm surgery. *J Neurosurg* 2002;96:988–92.
 55. Klopfenstein JD, Spetzler RF, Kim LJ, et al. Comparison of routine and selective use of intraoperative angiography during aneurysm surgery: a prospective assessment. *J Neurosurg* 2004;100: 230–5.
 56. Towgood K, Ogden JA, Mee E. Neurological, neuropsychological, and functional outcome following treatment for unruptured intracranial aneurysms. *J Int Neuropsychol Soc* 2005;11:522–34.
 57. Bellebaum C, Schaefers L, Schoch B, et al. Clipping versus coiling: neuropsychological follow up after aneurysmal subarachnoid haemorrhage (SAH). *J Clin Exp Neuropsychol* 2004;26:1081–92.
 58. Brilstra EH, Rinkel GJ, van der Graaf Y, et al. Quality of life after treatment of unruptured intracranial aneurysms by neurosurgical clipping or by embolisation with coils. A prospective, observational study. *Cerebrovasc Dis* 2004;17:44–52.
 59. Barrow DL. Bad science ISAT: the impact on neurosurgical practice. *Clin Neurosurg* 2004;51:126–31.
 60. Diring MN. To clip or to coil acutely ruptured intracranial aneurysms: update on the debate. *Curr Opin Crit Care* 2005;11:121–5.